

Veritas[®] Clinical Study

Case Series

Free TRAM Flap Breast Reconstruction Using the Synovis MCA[®] Venous Anastamotic Coupler and Abdominal Wall Reinforcement Using Veritas[®] Bovine Pericardium

M. Mark Mofid M.D., F.A.C.S.

INTRODUCTION AND PRINCIPLES

Tenets central to autogenous reconstructive surgery of the breast entail the provision of safe and reliable surgical procedures with aesthetically superior results and limited functional deficits at the donor site. Relative to implant-based procedures, autogenous options require longer operative interventions and recovery, donor site scars, and in the case of microsurgical procedures, advanced clinical skills, training and experience on the part of the surgeon. Advantages inherent to these more complex procedures include the avoidance of implant associated complications such as implant rupture, palpability, rippling and capsular contracture. In many cases, such as in the case of irradiated tissue beds, autogenous techniques provide the added benefit of restoration of the soft tissue envelope.

Numerous free tissue transfer options exist today for microsurgical reconstruction of the breast. Though the free transverse rectus abdominis myocutaneous (TRAM) flap procedure is perhaps the most commonly performed among them, various advantages and disadvantages are noted with other donor options such as deep inferior epigastric perforator (DIEP), superficial inferior epigastric artery (SIEA), and superior and inferior gluteal artery perforator (SGAP and IGAP) flaps.

The Synovis MCA[®] venous anastamotic coupler has been in use for over two decades. Many studies in the breast, head and neck, hand and lower extremity reconstructive literature have confirmed the safe and effective use of the coupler to improve anastamotic patency rates and to shorten the duration of surgical and ischemia time.^{1,2,3,4} The largest study to date of 1000 consecutive

microsurgical breast cases documents a venous thrombosis rate of 0.6% and no total flap losses.⁵ This compares very favorably to hand-sewn venous thrombotic rates in the literature of between 2 and 3%.⁶ Furthermore, a short learning curve is typically associated with use of the coupler and the average time for anastamosis is less than 5 minutes.⁷

Abdominal wall donor site morbidity is the most common complication associated with the free TRAM procedure. A meta-analysis of 1,920 DIEP flaps and 3,185 free TRAM flaps reports a 9.8% rate of abdominal bulge or hernia associated with free TRAM flaps and a 3.9% hernia/bulge rate associated with DIEP flaps. As expected, the tradeoff for decreased abdominal wall morbidity with DIEP flaps are the much higher combined rates of fat necrosis, total and partial flap loss of 14.6% versus 7.7% for free TRAM flaps.⁸ The balance between flap reliability and the potential for abdominal wall morbidity is typically judged by the surgeon in light of patient obesity, need for large-volume reconstructions, history of smoking, and the intraoperative assessment of abdominal wall perforators. Primary fascial closure and NON acellular dermal matrix (ADM) reinforcement techniques are found to have the highest rates of success for long term abdominal wall competence.⁹ The use of human and porcine ADM products for abdominal wall TRAM reinforcement have been found to be associated with high rates of infection, seroma formation, hernias, and delayed abdominal wall bulging and laxity.^{10,11} The use of non-biologic mesh for abdominal wall reinforcement or to bridge a defect is similarly associated with high rates of infection, exposure and failure over time.¹²

Ideal properties for biologic graft materials used in abdominal wall reinforcement include

- Resistance to infection, seromas and wound complications
- Rapidity of revascularization and incorporation into surrounding tissues
- Excellence of tensile strength and abdominal wall-prosthesis breaking strength
- Favorable expense, handling and preparation characteristics

The use of Veritas® bovine pericardium for abdominal wall reinforcement after free TRAM procedures is presented as a safe and reliable biologic graft material that integrates ideal properties for use in surgery.

Technique

When possible, free TRAM or DIEP flap reconstruction of the breast is performed using a two-team approach. While one team prepares the breast pocket and dissection of recipient vessels (internal mammary or thoracodorsal), the other team prepares the flap for harvest. In dissecting the flap, the TRAM skin island is elevated to expose the medial and lateral rows of perforating vessels. The anterior rectus fascia and rectus abdominis muscle are incised to include perforators, muscle and fascia as necessary per the surgeon's judgment for the preservation of flap blood supply. When possible, during free TRAM procedures a muscle splitting dissection is performed both laterally and medially. The inferior epigastric vessels are dissected their entire length to the external iliacs to maximize pedicle length.

With the division of donor vessels, ischemia time is begun. The donor artery is flushed with 100 u/cc of heparinized saline until effluence from the vein is clear. The recipient and donor vein are occluded with separate vascular clamps and placed in a position close to one another. A vessel measuring gauge is used to determine the correct coupler size. The diameter of the coupler selected should be slightly smaller than the measured diameter of the smaller vessel. Typically, a 2.5 mm or 3.0 mm coupler will be used. The donor vein is attached to the coupling component by pulling it through a ring and evenly everting it onto the pins in a tripartite fashion. The vessel is then hooked onto the remaining three pins. The identical procedure is then performed for the recipient vein. (Figure A)

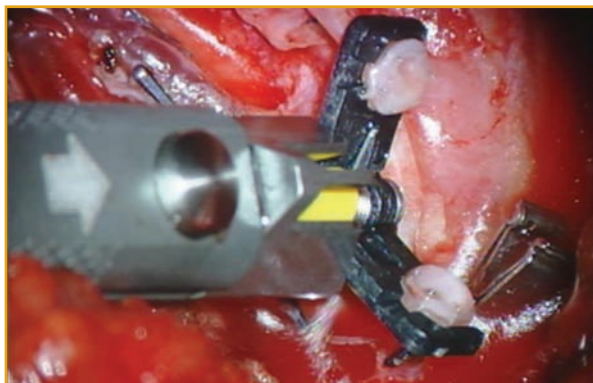


Figure A

Heparinized saline is used again to irrigate the vessel lumens. The instrument knob is then rotated to coapt the vessel ends. A mosquito clamp is used to compress the rings together as they are pushed out of the end of the instrument ensuring a tight apposition of interlocking pins and rings. (Figure B) A standard hand sewn arterial anastomosis is then performed, clamps released and inset of the flap performed.

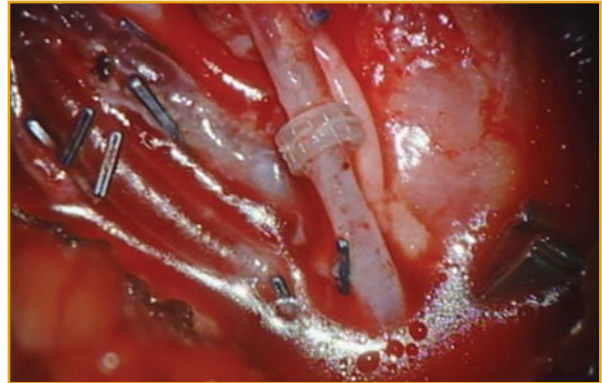


Figure B

Closure of the abdominal wall is performed with a strong preference for primary fascial closure whenever possible using 0 Ethibond or polypropylene suture in an inverted figure of eight pattern. Additional abdominal wall plication sutures are performed as needed to centralize the umbilicus. A triple antibiotic saline solution composed of 1L of sterile saline, 2 g of Ancef, 160 mg of Gentamicin and 100,000 units of Bacitracin powder is used to soak a piece of Veritas® that measures the length of the abdominal wall repair. Veritas® is secured circumferentially around the closure as an overlay using 2-0 PDS suture on an SH needle. Pie crusting of the material is performed using a #11 blade to enhance revascularization and ingrowth of the abdominal wall tissue through the product into Scarpa's fascia. (Figure C) Additional quilting sutures are

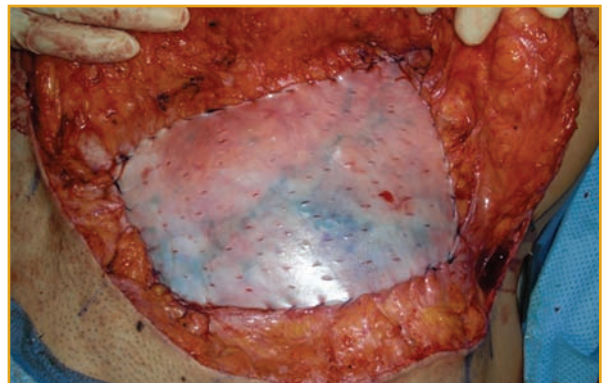


Figure C

performed as needed between the material and the abdominal wall. (Figure D) Progressive tension sutures using 2-0 Vicryl are placed between Scarpa's fascia and the abdominal wall to obliterate the potential space and to minimize the risk of seroma formation. A single drain is placed under the closure and exited through one end of the abdominal incision. The drain is typically left in place for 7 to 10 days until drainage is less than 30 cc/day.

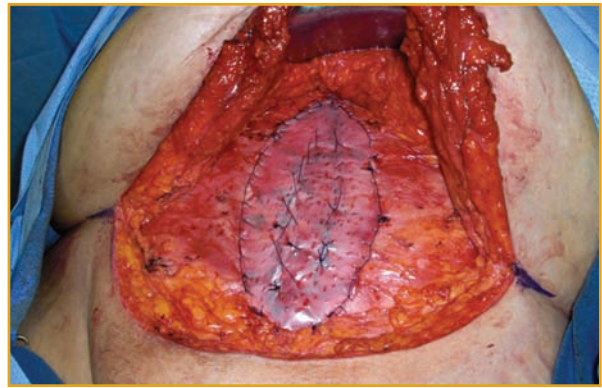


Figure D

Patient Presentations

1) This is a 59 year old female with squamous cell carcinoma of the right breast and axillary lymph node metastasis who underwent a right modified radical mastectomy and immediate reconstruction with a right breast muscle-sparing free TRAM. (Figure E) The Synovis MCA® venous anastamotic coupler was used for the microsurgical venous

anastomosis and Veritas® bovine pericardium was used as for abdominal wall reinforcement following primary fascial repair. One year follow up results are provided following nipple-areola reconstruction with skate flap using inner thigh donor full thickness skin graft. (Figure F)

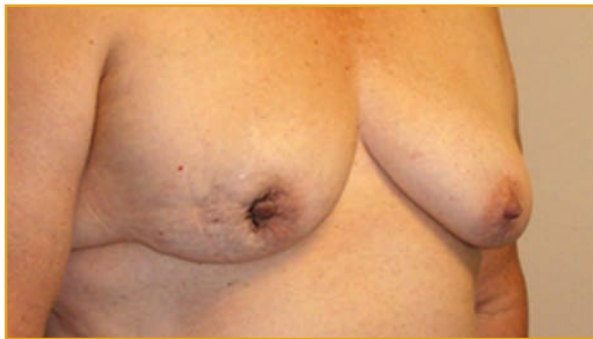

Figure E

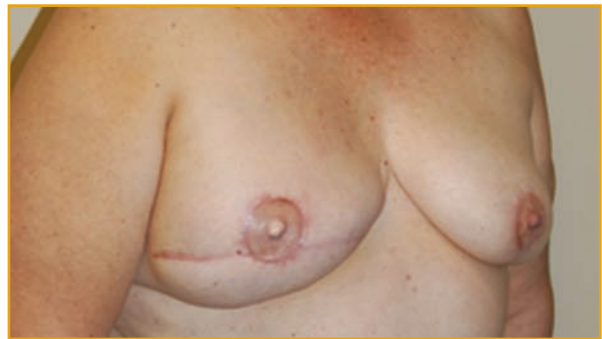

Figure F

2) This is a 45 year old female with a history of right breast multifocal DCIS status post bilateral total mastectomy and tissue expander/implant reconstruction at an outside institution. The patient was post operatively dissatisfied with shape and small size of her reconstructed breasts and desired to undergo a bilateral free TRAM procedure. (Figure G) Due to the patient's obesity, need for large volume reconstruction and intraoperative

perforator status, MS-1 muscle-sparing free TRAM's were performed preserving only the lateral rectus abdominis muscle bilaterally. (Figures H, I and J) The Synovis MCA® venous anastamotic coupler was used for both microsurgical venous anastomoses and Veritas® bovine pericardium was used as for abdominal wall reinforcement following primary fascial repair. Three month follow up photographs are presented. (Figure K)

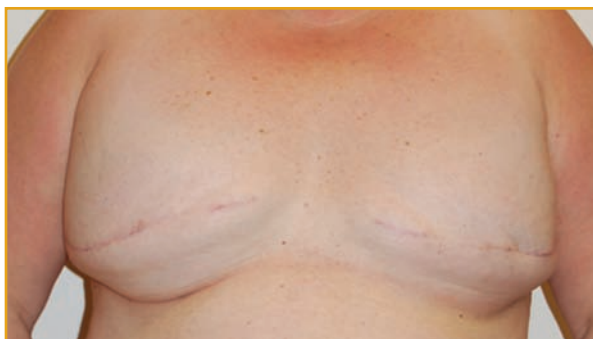

Figure G

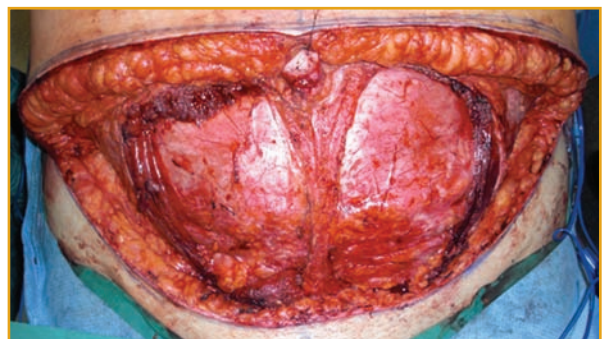

Figure H

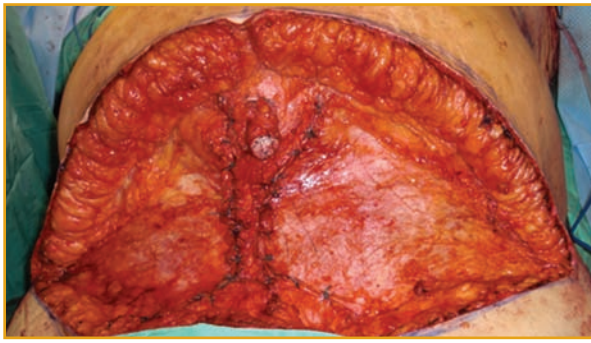


Figure I

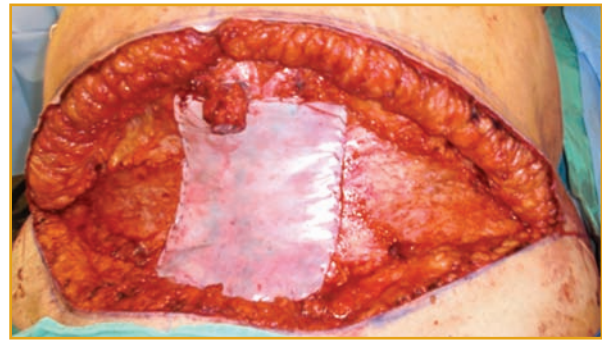


Figure J

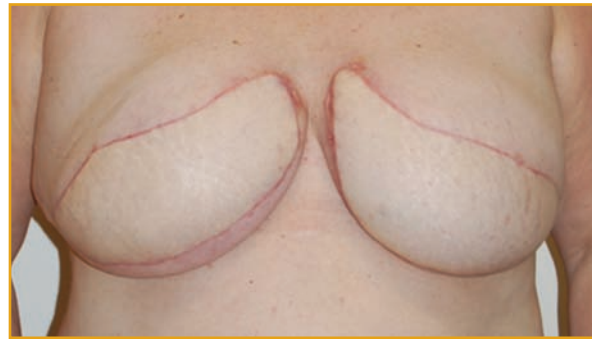

Figure K

CONCLUSION

The safe and reliable performance of microsurgical breast reconstruction using the free TRAM and DIEP procedures are enhanced using the Synovis MCA[®] venous anastomotic coupler and Veritas[®] bovine pericardium for abdominal wall reinforcement. Use of the coupler for venous anastomosis is associated with shorter ischemia times and lower rates of venous anastomotic thrombosis. Use of Veritas[®] bovine pericardium for abdominal wall reinforcement of the free TRAM

donor site is advocated to decrease the risk of abdominal wall laxity and hernias. A low rate of seromas, infections, wound complications, and delayed abdominal wall bulges is noted by this author. Excellent abdominal wall-prosthesis breaking strength¹³ has been documented in in vivo studies. Off the shelf use and expense characteristics make Veritas[®] an ideal product for use in reconstructive surgery of the abdomen.

¹De Brujin HP, Marck KW. Coupling the venous anastomosis: Safe and simple. *Microsurgery* 1996; 17:414.

²Shindo ML, Costantino PD, Nalbhone VP, Rice DH, Sinha UK. Use of a mechanical micro vascular anastomotic device in head and neck free tissue transfer. *Arch Otolaryngol Head Neck Surg.* 1996; 122:529.

³Denk MJ, Longaker MT, Basner AL, Glat PM, Karp NS, Kasabian AK. Microsurgical reconstruction of the lower extremity using the 3M micro vascular coupling device in venous anastomoses. *Ann Plast Surg.* 1995; 35:601.

⁴Lanzetta M. Use of the 3M precise micro vascular anastomotic system in hand surgery. *J Hand Surg (Am.)* 1995; 20:725.

⁵Jandali, S, Wu, LC, Vega, SL, Kovach, SJ, Serletti, JM. 1000 consecutive venous anastomoses using the micro vascular anastomotic coupler in breast reconstruction. *Plast Reconstr Surg.* 2010; 125:792.

⁶Kroll SS, Schusterman MA, Reece GP, et al. Timing of pedicle thrombosis and flap loss after free-tissue transfer. *Plast Reconstr Surg.* 1996; 98:1230.

⁷Ahn CY, Shaw WW, Berns S, Markowitz BL. Clinical experience with the 3M micro vascular coupling anastomotic device in 100 free-tissue transfers. *Plast Reconstr Surg.* 1994; 93:1481.

⁸Man, L, Selber, JC, Serletti, JM. Abdominal wall following free TRAM or DIEP flap reconstruction: A meta-analysis and critical review. *Plast Reconstr Surg.* 2009;124:752.

⁹Boehmler, JH, Butler, CE, Ensor, J, Kronowitz, SJ. Outcomes of various techniques of abdominal fascia closure after TRAM flap breast reconstruction. *Plast Reconstr Surg.* 2009; 123:773.

¹⁰Otterburn, D, Losken A. The use of porcine acellular dermal material for TRAM flap donor-site closure. *Plast Reconstr Surg.* 2009; 123:74e.

¹¹Chun Y. Implant-based breast reconstruction using acellular dermal matrix and the risk of postoperative complications. *Plast Reconstr Surg.* 2010; 125:499

¹²De Vries Reilingh TS, van Goor H, Charbon JA, Rosman C, Hesselink EJ, van der Wilt GJ, Bleichrodt RP. Repair of giant midline abdominal wall hernias: "components separation technique" versus prosthetic repair: interim analysis of a randomized controlled trial. *World J Surg.* 2007; 31:756.

¹³Gaertner, WB, Bonsack ME, Delaney JP. Experimental evaluation of four biologic prostheses for ventral hernia repair. *J Gastrointestinal Surg.* 2007; 10:1275.

Medical guidance presented is solely that of the author.

Provided as an educational service by:

Synovis[®]

Surgical Innovations

A Division of Synovis Life Technologies, Inc.

Veritas and MCA are registered trademark of Synovis Life Technologies, Inc.

Rx only.

See *Instructions for Use* for indications, warnings, precautions, side effects and contraindications.

88215A 07/10 ©2010 Synovis Surgical Innovations. All Rights Reserved. Printed in the USA.