

# *Abdominoplasty Revision Using Tissue Expansion*

**Omar Marwan Kadri, Setara Moosa & M. Mark Mofid**

**Aesthetic Plastic Surgery**


ISSN 0364-216X

Volume 37

Number 3

Aesth Plast Surg (2013) 37:538-540

DOI 10.1007/s00266-013-0104-6



**Your article is protected by copyright and all rights are held exclusively by Springer Science+Business Media New York and International Society of Aesthetic Plastic Surgery. This e-offprint is for personal use only and shall not be self-archived in electronic repositories. If you wish to self-archive your article, please use the accepted manuscript version for posting on your own website. You may further deposit the accepted manuscript version in any repository, provided it is only made publicly available 12 months after official publication or later and provided acknowledgement is given to the original source of publication and a link is inserted to the published article on Springer's website. The link must be accompanied by the following text: "The final publication is available at [link.springer.com](http://link.springer.com)".**

## Abdominoplasty Revision Using Tissue Expansion

Omar Marwan Kadri · Setara Moosa ·  
M. Mark Mofid



Received: 4 November 2012 / Accepted: 25 February 2013 / Published online: 22 March 2013  
 © Springer Science+Business Media New York and International Society of Aesthetic Plastic Surgery 2013

**Abstract** Postoperative revision after abdominoplasty may be necessary at times to improve contour, remove asymmetries, revise the umbilicus, or improve the scar. This report describes the case of an abdominoplasty performed outside the United States that resulted in an inappropriately high and unattractive scar with an elevated pubic hairline. The patient presented to our clinic 2 years after her initial surgery, and a scar-lowering procedure was performed with the assistance of tissue expansion. The reconstructive effort was staged over a period of 4 months, with an initial procedure to repair several hernias, bury the umbilicus, and place a tissue expander. Over several months, 3.5 L of expansion was performed. During a subsequent surgery, the tissue expander was removed, and the scar was successfully lowered and improved. The healing was uneventful, and the patient was satisfied with the outcome. The final result is exhibited in 1-month follow-up photographs.

**Level of Evidence V** This journal requires that authors assign a level of evidence to each article. For a full description of these Evidence-Based Medicine ratings, please refer to the Table of Contents or the online Instructions to Authors [www.springer.com/00266](http://www.springer.com/00266).

**Keywords** Abdominoplasty revision · Scar-lowering procedure · Tissue expansion

Abdominoplasty is the fourth most common aesthetic surgical procedure performed by American Society of Plastic Surgeons (ASPS) member surgeons, with nearly 116,000 procedures performed in 2010 [1]. Although the vast majority of these surgical procedures are performed without any complications, patients may at times present with high or excessively widened surgical scars from incisions placed too high on the abdomen or from excessive removal of lower abdominal tissue. In these cases, a simple scar revision is an inadequate measure for lowering of the abdominoplasty scar due to an inherent deficit in the amount of tissue remaining for resurfacing of the abdomen.

The use of tissue expanders for abdominal wall reconstruction is an accepted and previously published technique for cases with large hernias and loss of abdominal domain [2, 3]. These applications have included treatment for herniation, correction of burn-related scars, and abdominal wall defects from omphalocele or trauma [3–6]. To our knowledge, the use of tissue expanders to lower the abdominal scar has not been described previously.

This case report describes a technique for lowering the abdominal scar through a staged intervention involving placement of the tissue expander in the central upper abdomen during the first procedure, with removal of the tissue expander and use of recruited abdominal skin to lower the scar during the second procedure.

### Case Report

A 43-year-old woman presented with a medical history significant for lower back pain and treatment with a spinal

---

O. M. Kadri  
David Geffen School of Medicine at UCLA, Los Angeles, CA,  
USA

S. Moosa  
San Diego Skin, Inc., 4150 Regents Park Row, Suite #300,  
La Jolla, CA 92037, USA

M. M. Mofid (✉)  
Division of Plastic Surgery, University of California, San Diego,  
4150 Regents Park Row, Suite #300, La Jolla, CA 92037, USA  
e-mail: [drmmofid@mofidplasticsurgery.com](mailto:drmmofid@mofidplasticsurgery.com)

cord stimulator. She had undergone an abdominoplasty in 2006, with a postoperative course complicated by wound-healing problems per the patient's recollection.

At presentation, she reported abdominal pain, poor scarring, an elevated pubic hairline, and a high and unsightly scar. A staged procedure was recommended requiring an initial surgery to place the tissue expander and temporarily bury the umbilical stalk, followed by a second procedure to remove the tissue expander, replace the umbilicus, and use recruited skin to lower the scar.

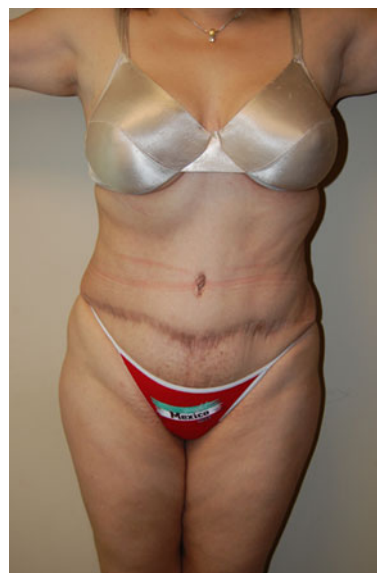In March 2008, the patient underwent her initial surgery by the senior author of this study for placement of the tissue expander. At exploration of the abdominal wall, multiple deformities of the abdominal wall were identified including a large umbilical hernia as well as fascial separation and stripping at multiple sites throughout the abdominal wall.

An umbilical hernia repair was performed with 0 Ethibond suture, and an overlay of Veritas bovine pericardium (Baxter Healthcare Corporation, Deerfield, IL) was placed throughout the abdomen over the repairs of the fascial separation. The umbilicus itself was closed with 3-0 Monocryl, and the umbilicus site on the abdominal skin flap was repaired and closed also with 3-0 Monocryl. A 2.25-L PMT tissue expander (PMT/Penmark Corporation, Chanhassen, MN) was collapsed and secured with 2-0 PDS suture to fix tabs within the central upper abdomen and a remote port located inferiorly and laterally to the patient's left above the scar. A drain was exited through the right side of the closure.

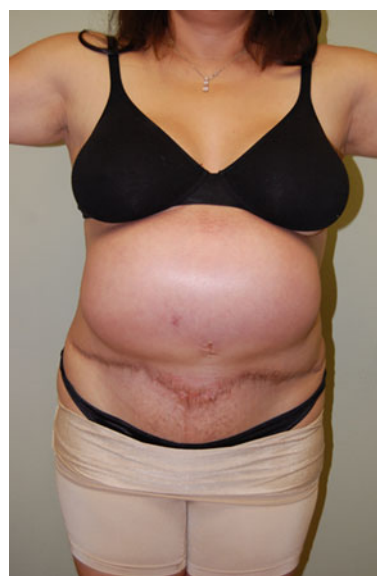On postoperative day 4, the drain was removed. Then 4 weeks later, tissue expansion was started with an initial 1-L fill of injectable sterile normal saline. Over the subsequent 3 months, additional 500-mL fills of injectable sterile normal saline were performed biweekly to a final overexpanded fill volume of 3.5 L within the tissue expander.

The patient reported pain, anorexia, and early satiety during the expansion process, which was attributed to pressure on the abdominal wall and stomach from the tissue expander. Otherwise, she had no other complaints and did well during the intervening period between the first and second surgeries.

In July 2008, the second surgical intervention was performed by the senior author of this study, and the tissue expander was removed. The umbilicus was reopened and found to have intact dermis and epidermis within the stalk. In the next step, 420 g of lower abdominal tissue below the old scar was excised, the abdominal skin flap was lowered, and a new site for the umbilicus within the abdominal skin flap was created. A partial capsulectomy was performed under the abdominal skin flap to allow for enhanced skin



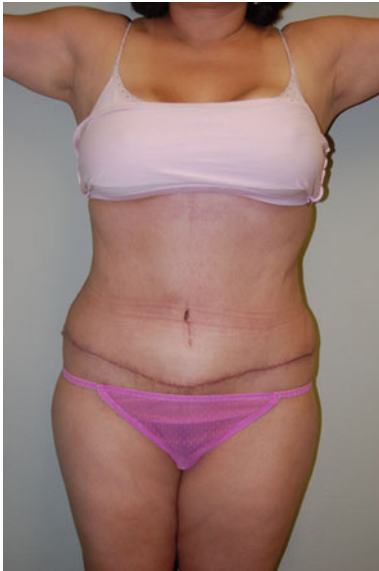**Fig. 1** Preoperative view of a 43-year-old woman in 2008, 2 years after abdominoplasty performed outside the United States



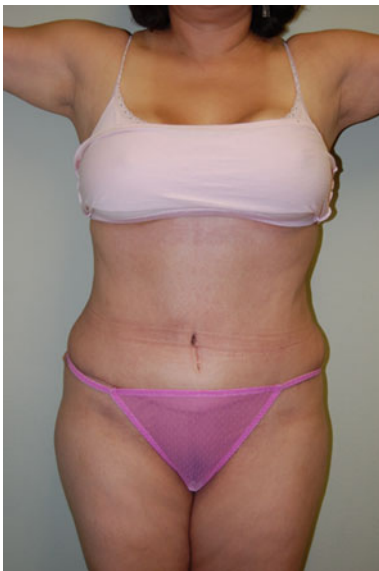**Fig. 2** Patient with a central *upper* abdominal tissue expander filled to 3.5 L

flap mobility and to prevent a postoperative seroma. A drain was exited through the right side of the incision.

The patient's postoperative course was unremarkable except for high drainage outputs that prevented drain removal until postoperative day 16. After drain removal, no seroma occurred. Approximately 2 months later, a small left hip dog ear was revised in an office-based procedure with the patient under local anesthesia. Figures 1, 2, 3, 4 present views before surgery and 1 month afterward.



**Fig. 3** Postoperative views 1 month after abdominoplasty



**Fig. 4** Postoperative views 1 month after abdominoplasty

## Discussion

As described by Ramirez [7], one objective of an aesthetically pleasing abdominoplasty is placement of the incision within the bikini line. For patients whose abdominoplasty incision was placed too high, the options for lowering the scar are limited. Although tissue expanders have been used successfully for abdominal wall reconstruction in cases that had limited soft tissue coverage [2], they have not been described to date in the revision of an abdominoplasty scar. Expansion-associated pain with the abdomen is less severe

than with the distal extremities due to the inherent extensibility of the tissue.

The frequency of more rare complications associated with tissue expansion such as implant failure, neuropraxia, and infection vary by the anatomic site, with the trunk tolerating tissue expansion quite well [8]. This technique may be limited in terms of how much skin can be recruited for effective lowering of a high abdominoplasty scar and might be contraindicated for patients with a known history of gastroesophageal reflux disease. Due to the expense associated with two surgeries and the use of a tissue expander, as well as the unlikely coverage of this elective surgery by third party payors, it also may be cost prohibitive for certain patients who might otherwise be candidates for the procedure.

## Conclusions

We present a novel technique using tissue expansion to lower an abdominoplasty scar after an initially unsatisfactory result for the procedure performed outside the United States. The successful use of this technique should serve as an encouragement to other plastic surgeons who have been frustrated by this vexing problem.

**Disclosure** The senior author of this study (M.M.M.) serves on the speakers bureau and is a consultant for Baxter, the maker of Veritas bovine pericardium.

## References

1. American Society of Plastic Surgeons. Procedural statistics, 2001–2011. Available at: <http://www.plasticsurgery.org/News-and-Resources>. Accessed 9 June 2012
2. Rodriguez ED, Bluebond-Langner R, Silverman RP et al (2007) Abdominal wall reconstruction following severe loss of domain: the R Adams Cowley Shock Trauma Center algorithm. *Plast Reconstr Surg* 120:669–680
3. Ali JM, Stabler A, Hall NR, Irwin M, Miller R, Fearnhead NS (2012) Tissue expanders: early experience of a novel treatment option for perineal herniation. *Hernia*. doi:10.1007/s10029-012-0939-9
4. Clifton MS, Heiss KF, Keating JJ, Mackay G, Ricketts RR (2011) Use of tissue expanders in the repair of complex abdominal wall defects. *J Pediatr Surg* 46:372–377
5. Rivera R, LoGiudice J, Gosain AK (2005) Tissue expansion in pediatric patients. *Clin Plast Surg* 32:35–44, viii
6. Freitas RdS, Cruz GAdOe, Scomação I, Nasser IJG, Colpo PG (2011) Tissue expansion at Hospital de Clinicas-UFPR: our experience. *Revista Brasileira de Cirurgia Plástica* 26:407–410
7. Ramirez OM (2000) Abdominoplasty and abdominal wall rehabilitation: a comprehensive approach. *Plast Reconstr Surg* 105:425–435
8. Antonyshyn O, Gruss JS, Mackinnon SE, Zuker R (1988) Complications of soft tissue expansion. *Br J Plast Surg* 41:239–250